



Article

## **Deltoid hibernoma of atypical presentation: Clinical Case**

Sergio Heinar Rodríguez-Sosa, Alexis Emir Nogueira-Echeverría, Héctor Armando Rubio-Zapata, Adriana Teresa Cruz-Mendez, Camilo José Rodríguez-Herrera, Raúl Alfonso Vidales-López, Francisco José Pat-Cruz, Santiago Díaz de Sollano-Shivy, Guillermo Padrón-Arredondo \*

Hospital-Clinic Mérida, 21 Street, Sulá Commissary, Mérida, Yucatán, PC 97249, México; [gpadronarredondo@hotmail.com](mailto:gpadronarredondo@hotmail.com)

**Abstract:** INTRODUCTION. Hibernoma, a benign tumor of brown fat, first described as “pseudolipoma” by Merkel (1906), was named “hibernoma” by Gery (1914) due to its morphological resemblance to brown fat observed in hibernating animals. They are uncommon, accounting for <2% of benign lipomatous tumors and 1% of all adipocytic tumors. CLINICAL CASE. Soft tumor in the right anterior deltoid region, 8x10 cm, ovoid in shape, does not beat or fluctuate, nor adheres to deep planes, painful movement and becomes more evident with flexion-abduction-external rotation of the right upper limb. Abscessed Cystic Lesion, covered by fibrous and calcified wall. Encapsulated and Sclerosed Abscess Wall. Negative for Malignancy. The patient evolved satisfactorily. The stitches were removed 14 days later and he returned to his usual activities 2 months after the operation. DISCUSSION. In a case of hibernoma, radiographs do not show calcifications or bone erosion. Ultrasonography of a hibernoma reveals a well-circumscribed, uniformly hyperechogenic mass. On computed tomography, the lesion is usually lobulated, septate, and well-defined, with fat density and variable contrast enhancement. On T1-weighted MRIs, Hibernoma appear hypo intense with respect to fat, whereas on T2-weighted images they are usually is intense with respect to subcutaneous fat. Radiological and histological differential diagnoses of Hibernoma include other benign soft tissue tumors such as lipomas, rhabdomyomas, neurofibromas, fibromas, hemangiomas, as well as malignant tumors including well-differentiated liposarcomas or metastatic carcinoma.

**Keywords:** hibernoma; lipoma; brown fat tumor; benign tumor; soft tissue tumor.

## 1. Introduction

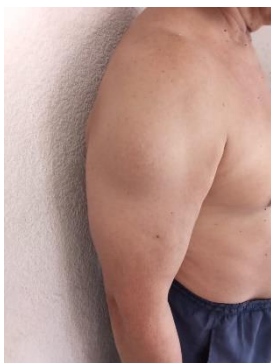Hibernoma, a benign tumor of brown fat, first described as “pseudolipoma” by Merkel (1906), was named “hibernoma” by Gery (1914) due to its morphological resemblance to brown fat observed in hibernating animals. They are rare and represent <2% of benign lipomatous tumors and 1% of all adipocytic tumors (1).

It is accepted that there are two types of adipose tissue: white fat and brown fat. Brown adipose tissue was first described by Welsh in 1670. It is suggested that brown tissue participates in the regulation of metabolism and thermogenesis, being abundant in hibernating animals, although it has also been described in non-hibernating animals, such as the man, mainly in newborns, infants and children. In humans it decreases markedly after eight weeks of life, although there are still small amounts in all age categories (in adults it accounts for 1% of body mass). These remains are located mainly in the armpits, interscapular and inguinal region. For this reason, hibernoma is located in these regions, although they can also be found on the scalp, jaw, neck, shoulder, back, mediastinum, retroperitoneum, around the ureter, and thigh (2).

Hibernomas are soft tissue tumors, clinically they tend to be slow-growing, painless, defined on palpation, soft and mobile, with a size between 5 and 10 cm. 10% are intramuscular, they are generally rare in frequency, although they are easy to diagnose by pathology, due to their histological characteristics. There are no known malignancy criteria, so it is accepted as a benign tumor of brown fat. They are common in middle-aged adults with equal gender distribution, with an average tumor size of 9.3 cm (1-24), with a predilection for the subcutaneous tissue of the thigh, upper trunk, and neck (3, 4).

Clinically, hibernomas are slow-growing, painless, usually well-defined, soft, and mobile tumors. Its color varies depending on the amount of intracellular lipids. Microscopically, they are identified by their characteristic lobular pattern and are composed of round or oval cells with eosinophilic, granular, or multivacuolated cytoplasm; with small centrally placed nuclei (5).

## 2. Clinical Case



61-year-old male. Qx: Appendectomy (1983), allergies denied.

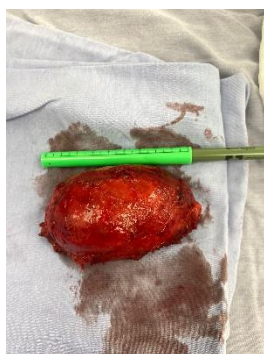
Suffering begins with an increase in volume in the right shoulder of four years of evolution, painful to mobilization for which he is referred to this unit.

On FE: Soft tumor in the right anterior deltoid region, 8x10 cm, ovoid in shape, does not beat or fluctuate, nor adheres to deep planes, painful movement and becomes more evident with flexion-abduction-external rotation of the right upper limb.

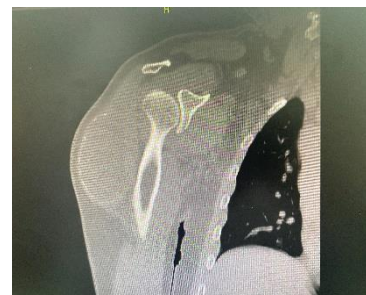Laboratories: normal. USG: solid mass 77x40x53 mm, volume 87.5 cc, at the expense of an echogenic component and a hypoechoic component with dimensions 33x17x20 mm, volume

6 cc with lobulated edges. Having heterogeneous composition, it does not typically behave like Lipoma.

CT: rounded lesion with calcified edges presenting a liquid level inside due to fat and blood content between the deltoid fibers measuring 7.8x4.5 cm, without affecting adjacent structures.



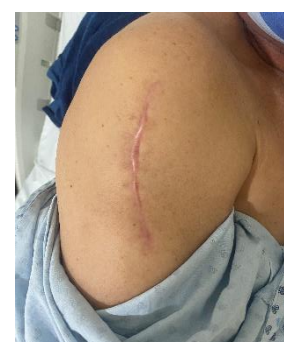With the support of the Trauma and Orthopedics Service, surgery was performed electively, under general anesthesia, a 15 cm long longitudinal incision was made on the right anterior deltoid surface, a trans deltoid approach was performed, the entire tumor was dissected without releasing content towards surgical bed; finding an encapsulated



tumor with smooth non-vascular edges of 15x10 cm, hemostasis is verified, it is closed by planes up to the skin.

The patient was discharged after the anesthetic effect with antibiotic therapy and pain management. His postoperative period was uneventful. Sample is sent to the Pathology service.

Biopsy: abscessed cystic lesion, covered by fibrous and calcified wall. Encapsulated and Sclerosed Abscess Wall. Negative for Malignancy



The patient evolved satisfactorily. The stitches were removed 14 days later and he returned to his usual activities 2 months after the operation.

### 3. Discussion

Subcutaneous lipomatous lesions are commonly found in clinical practice. Hibernoma is a rare subtype of benign lipomatous tumor, representing 1% of all types. It is challenging due to the difficulty of differentiating it from atypical lipomatous lesions and liposarcomas, which can lead to a possible inappropriate diagnosis (6).

Macroscopically, it is an encapsulated, homogeneous tumor with a lobulated, yellowish-brown surface and a soft consistency. Diagnostic criteria for hibernomas include a circumscribed, lobulated, yellow-brown mass with cellular features of brown fat, including numerous small cytoplasmic vacuoles and eosinophilic granular cytoplasm. Ward white fat cells [12]. The lipoma-like hibernoma variant has a large number of non-vacuolated cells mixed with few multivacuolated granule cells of brown fatty-appearing hibernoma (7).

Cytogenetically, hibernoma is characterized by abnormalities on chromosome 11q13 that probably correspond to a tumor suppressor gene. This chromosomal region is co-located with the multiple endocrine neoplasia type 1 (MEN1) gene, but the "MEN-hibernoma" association has not yet been demonstrated (8).

From the study of hibernoma in different locations, it can be inferred that it is a benign tumor with no tendency to recur or metastasize, even when excision has been incomplete, an assertion supported by extensive series, among which we highlight the AFIP series. These

are soft tissue tumors with a preferential location in the deep dermis or subcutaneous tissue, although their intramuscular location is not uncommon. In this case, there is a striking infiltration of the striated muscle bundles typical of the oral location (9, 10).

Hibernomas are lobulated, well-circumscribed, partially encapsulated neoplasms with a yellowish-brown rubbery texture with an average size of 9 cm. Within typical S100 protein positivity in both eosinophilic and pale cells with variable intensity and CD34 negativity (11). In a case of hibernoma, radiographs do not show calcifications or bone erosion. Ultrasonography of a hibernoma reveals a well-circumscribed, uniformly hyperechogenic mass. On computed tomography, the lesion is usually lobulated, septate, and well-defined, with fat density and variable contrast enhancement. On T1-weighted MRIs, hibernomas appear hypointense with respect to fat, whereas on T2-weighted images they are usually isointense with respect to subcutaneous fat. Radiological and histological differential diagnoses of hibernomas include other benign soft tissue tumors such as lipomas, rhabdomyomas, neurofibromas, fibromas, hemangiomas, as well as malignant tumors including well-differentiated liposarcomas or metastatic carcinoma. (12-15).

Hibernomas are a rare benign tumor that arises from remnants of brown adipose tissue. They usually occur on the thigh, upper trunk, and neck. To the best of our knowledge, rib hibernoma is rare in the literature. The mechanism of hibernoma has not been elucidated. Hibernomas occur most often in adults 40 to 70 years of age and most common in men. Intraosseous hibernomas are mostly asymptomatic and incidentally detected on imaging. Hibernomas present clinically as an asymptomatic soft tumor, and symptoms are present when adjacent structures are compressed. This tumor was located at the lower margin of the rib and close to the parietal pleura. The preoperative pain in this patient may be due to compression of the local periosteum or pleura by the intraosseous rib hibernoma (16, 17).

The treatment of choice is local resection of the tumor; with meticulous hemostasis, identification of the feeding vessels; with prevention of hematomas and extra compartmental contamination. The prognosis is good, since no recurrences or metastases have been reported. Differentiation between hibernomas and atypical lipomatous tumor/well-differentiated liposarcoma (TL/LSBD), especially when they have a heterogeneous appearance on CT and MRI. Branching of flow voids and enhancement of vascular structures may favor hibernoma over LSBD. Both TL/LSBD and hibernomas may contain thick, raised septa. Aggressive ALT can present with local invasion, metastasis, and regional metastasis. When imaging is inconclusive, an image-guided biopsy or open biopsy should be considered. Due to the reported cases of arteriovenous shunting, it has been suggested that core needle biopsy should be avoided in deep lesions (18, 19).

**Funding:** This research received no external funding.

**Conflict of interest:** No conflict of interest.

#### **References:**

1. Gómez Sotelo, A. I., Caba Molina, M., Romera López, A. L., Pérez Ramón, J. A., &

- Rodríguez Morillas, D. Hibernoma retroperitoneal. *Cirugía Española*, 2010; 88(5):345-6. doi:10.1016/j.ciresp.2010.01.004
2. Nelson-Vidal C, Tirapequi S, Torche VM, Urquieta MK, Lanzarini SE. Hibernoma. Presentación de dos casos clínicos. *Rev Chil Cir*. Jun 2004; 56(3):279-82.
  3. Al Hmada Y, Schaefer IM, Fletcher CDM. Hibernoma Mimicking Atypical Lipomatous Tumor: 64 Cases of a Morphologically Distinct Subset. *Am J Surg Pathol*. 2018 Jul; 42(7):951-7. Doi: 10.1097/PAS.0000000000001061.
  4. Hernández-Rocha FI, Rodríguez-Sánchez JR, Cervantes-Moreno S. Hibernoma. Reporte de un caso. *Rev Méd Sinergia*, abril 2023; 8(4): e1007. <https://doi.org/10.31434/rms.v8i4.1007>.
  5. Marques-da Silva DV, Azevedo-Cordova JL, Ferreira-Vasconcelos LH, Martins de Menezes F, Pereira-Bastos PS, Chimeli-Ormonde L. Spigelian hernia diagnosis: Case report. *Int J Surgery Case Rep*, 2023; 106: 108-65.
  6. Abdullah Saleh AlQattan, Alaa A. Al Abdrabalnabi, et al. A Diagnostic Dilemma of a Subcutaneous Hibernoma: Case Report. *Am J Case Rep*, 2020; 21: e921447. Doi: 10.12659/AJCR.921447
  7. Gabra, A, Sacasa A, Mirza B, Kleinstein E. Lipoma-like hibernoma: a rare soft tissue tumor—a case series and review of the literature. *J Surg Case Rep*, 2023; 5: 1-4
  8. Elafram R, Khessairi Na, Romdhane MB, Sghaier M, Hamd. The lipoma-like hibernoma:
  9. Torres-Gómez FJ, Torres-Gómez A, Torres-Olivera FJ. Hibernoma de cavidad oral. Una entidad Infrecuente. *Rev Esp Cir Oral Maxilofac*, 2016; 38(1):82-4.
  10. Shahnaz M, Shalini N, Shereefa AQ, Vikas K. Oral hibernoma along with multiple lipomas. *J Oral Maxillofac Pathol*, 2023; 27:S20-3.
  11. Hanna S, Davies A, Diab J, Clement Z. Breast Hibernoma in a male patient: a rare case report and review of the literature. *J Surg Case Rep*, 2023; 5: 1-6 <https://doi.org/10.1093/jscr/rjad239>
  12. López Piloto O, Cruz Hernández TM, López Poza M. Hibernoma dorsal gigante. Presentación de caso. *Rev Chil Neurocir*, 2019; 42(1), 64-7. <https://doi.org/10.36593/rev.chil.neurocir.v42i1.96>
  13. Martínez Álvarez A, León Piñeiro M, Candeau Tamayo PA. Hibernoma intramuscular en el muslo izquierdo de una fémina. *MEDISAN*, 2021; 25(5):1189.
  14. Alonso-Recio A, Mingo-Robinet J, Baruque-Astruga M, Briso-Montiano R. Hibernoma en el muslo, reporte de caso clínico. *Rev Colomb Ortop Traumatol*, 2022; 36:114-7.
  15. Pujani M, Khan S, Jetley S, Raina P, Jetley S. Intramuscular Hibernoma of the Scapular Region Misdiagnosed on Cytology as a Malignant Lesion: A Report of a Rare Case. *Iran J Pathol*, 2017; 12(4): 396-9.
  16. Song M, Liu H, Zhang L, Gao L. Intraosseous hibernoma in the rib. *Interdisciplinary CardioVasc Thorac Surg*, 2023; 36(1): ivac287. <https://doi.org/10.1093/icvts/ivac287>
  17. Samargandi R, Le Nail L, de Pinieux G, et al. Intraosseous Hibernoma: A Rare Entity in Orthopedics with Peculiar Radiological Features. *Cureus*, June 02, 2023; 15(6):e39883. DOI 10.7759/cureus.39883
  18. Dabboucy B, Yazbeck M, Fares Y, et al. Rare Spinal Epidural Hibernoma: A Case Report. *Spine Surg Relat Res*, 2023; 7(1):113-5. [dx.doi.org/10.22603/ssrr.2022-0135](https://doi.org/10.22603/ssrr.2022-0135)

19. Tafti D, Cecava ND. Hibernoma. 2023; Jan 16. In: StatPearl. Treasure Island (FL): StatPearls Publishing; 2023 Jan– PMID: 34033341.